

A patient with acquired factor X deficiency and metastatic carcinoma of the bladder : is there a link between metastasis and factor deficiency in solid tumours?

T. Cammaert, MD and K.M.J. Devreese, MD, PhD

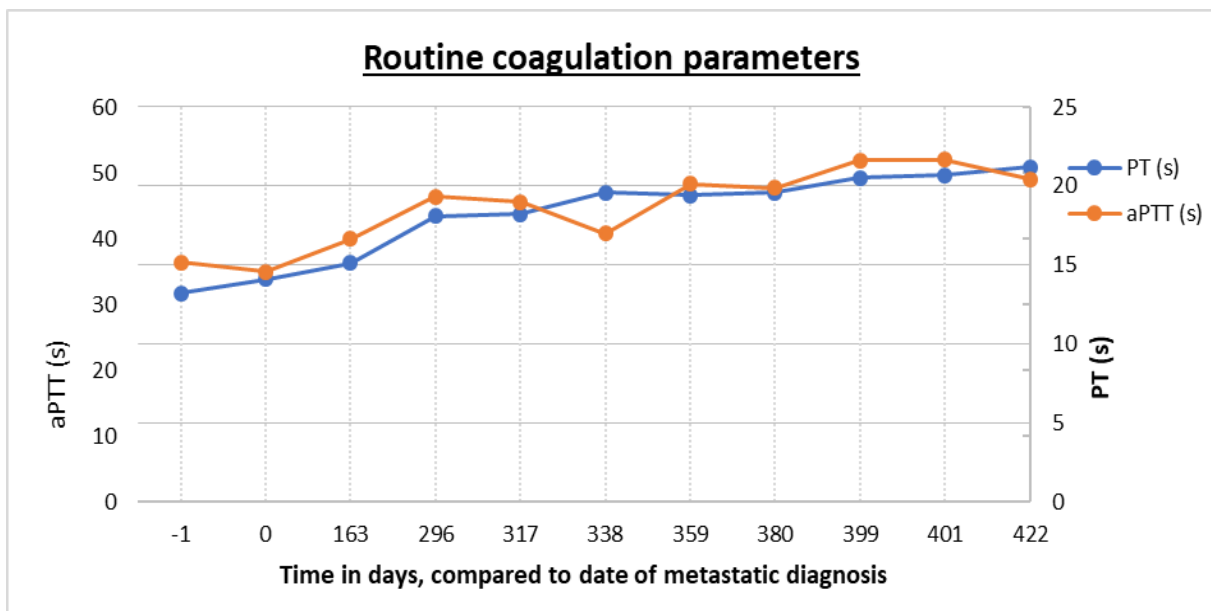
Coagulation Laboratory, Ghent University Hospital, Ghent, Belgium

Acquired deficiency of factor X is commonly found during antivitamin K therapy for the prevention of thrombosis or as a consequence of liver disease [1]. Less frequently, it has been observed as an isolated deficiency in a number of disease states. It has been associated with amyloidosis and haematological malignancies [2], and a few non-amyloid-related cases have been reported. Association with solid tumours is rare [3,4,5]. We would like to present a patient with a transitional cell carcinoma who developed a factor X deficiency.

A 67-year-old man was diagnosed with a localised transitional cell carcinoma of the bladder. He was first admitted to our hospital in January 2014 for a second-opinion consultation. Transurethral resection of the bladder took place and neoadjuvant chemotherapy was administered at our hospital, followed by a cystectomy. During follow-up suspicious lesions were noticed on medical imaging and a lung biopsy was carried out. Pathological examination revealed a metastasis of the transitional cell carcinoma. The patient subsequently received stereotactic body radiotherapy to all the lung lesions, yet had progressive disease 6 months later. He was then enrolled in a clinical trial in which he received pembrolizumab (Keytruda) and stereotactic body radiatiotherapy to one lung lesion according to the study protocol [6].

During follow-up prothrombin time (PT), activated partial thromboplastin time (aPTT) and fibrinogen concentration were measured to assess his blood clotting status. First measurements were within reference ranges, but after the lung metastases were noticed and prior to administration of pembrolizumab, a prolongation of the PT (20 sec; reference range 11.5 – 14.5 sec) and aPTT (50 sec; reference range 28.9-38.1 sec) was detected. Vitamin K was administrated but could not correct the PT or aPTT.

In the laboratory diagnostic work-up, mixing patient’s plasma with normal pooled plasma showed a correction of the aPTT (37.6 sec) and PT (14.2 sec). Clotting-factor activities for the extrinsic factors were determined by a one-stage clotting assay in a 1:10 sample predilution. FII, V and VII levels were within normal ranges with 105%, 71% and 98% activity, but FX activity was 21 % (all factor reference ranges 70-120%). Testing was repeated in a higher predilutions of 1:40 and 1:100, without increase of FX activity (20%). These



findings were confirmed on a control sample three weeks later.

In FX deficiencies, FX activity correlates relatively well with bleeding and may be provoked by levels lower than 10 per cent [1,7]. If no active bleeding is diagnosed, as in our patient, careful monitoring and treatment of the underlying disease are sufficient. If bleeding occurs, it can be treated with prothrombin complex concentrate or plasma, keeping the target factor X level above 20 per cent of the normal reference population [7].

This is, to our knowledge, the first case of an acquired deficiency of factor X associated with an urothelial carcinoma. We suggest that there might be a link with the metastasis of solid tumours [4,5], as the FX deficiency occurred simultaneously with the presence of metastases, in accordance with the previously published articles discussing this deficiency in solid tumours with metastasis. This theory is consistent with the status quo of the lab results and progressive lesions on medical imaging.

Based on the article

Cammaert T, Decaestecker K, Sundahl N, Rottey S, Devreese K. A patient with acquired factor X deficiency and metastatic transitional cell carcinoma of the bladder : is there a link between metastasis and factor deficiency in solid tumours? *Annals of Hematology* 2018, 97: 545-546.

References:

1. Uprichard J, Perry DJ. Factor X deficiency. *Blood Rev.* 2002 Jun;16(2):97-110. Review.
2. Furie B, Greene E, Furie B. Syndrome of acquired factor X deficiency and systemic amyloidosis in vivo studies of the metabolic fate of factor X. *N Engl J Med.* 1977 Jul 14;297(2):81-5.
3. Coucke L, Trenson S, Deeren D, Van haute I, Devreese K. Life-threatening bleeding tendency provoked by an acquired isolated factor X deficiency associated with respiratory infection. *Ann Hematol.* 2013 Oct;92(10):1437-8.
4. Korte W, Flury R. Acquired factor X deficiency and disseminated intravascular coagulation in a case of metastasizing carcinoma of the stomach and its course under chemotherapy. *Ann Hematol* 1992; 64: 152-4.
5. Stefanini M, Wiggishoff CC. Stuart factor (factor X) deficiency associated with renal and adrenal cortical insufficiency. *Ann Intern Med* 1966; 64: 1285-91.
6. Sundahl N, De Wolf K, Rottey S, Decaestecker K, De Maeseneer D, Meireson A, et al. A phase I/II trial of fixed-dose stereotactic body radiotherapy with sequential or concurrent pembrolizumab in metastatic urothelial carcinoma: evaluation of safety and clinical and immunologic response. *J Transl Med.* 2017 Jun 29;15(1):150.
7. Henson K, Files J, Morrison F. Transient acquired factor X deficiency: report of the use of activated clotting concentrate to control a life-threatening hemorrhage. *Am J Med.* 1989 Nov;87(5):583-5.